
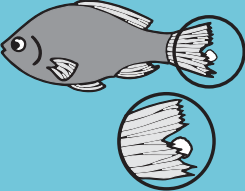












DIAGNOSING & TREATING SICK FISH

APPEARANCE	DESCRIPTION	SUGGESTED TREATMENT	CAUSATIVE AGENT
 <p>Fungal Infection</p>	<ul style="list-style-type: none"> Whitish cottony tufts or patches appear on the mouth, skin and fins of tropical fish, goldfish and koi. 	<p>PIMAFIX™</p>	<p>True fungal infections are caused by <i>Saprolegnia</i> and <i>Achlya</i> species.</p>
 <p>Fin and Tail Rot</p>	<ul style="list-style-type: none"> Fins appear ragged and split. Disease can progress until fins and tail are completely eroded. Secondary fungal infections commonly occur. 	<p>MELAFIX™</p> <p>For an alternative medication, select one of the following treatments: PIMAFIX, FURAN-2™, TRIPLE SULFA™, E.M. ERYTHROMYCIN™ or FIN & BODY CURE™.</p>	<p>Several bacteria infections can cause degradation of the fins and tails of fish. These pathogens include <i>Flavobacterium</i>, <i>Nocardia</i>, <i>Mycobacterium</i> and <i>Pseudomonas</i> species.</p>
 <p>Flukes/Parasitic Worms</p>	<ul style="list-style-type: none"> Most parasitic worms are not visible without the aid of a microscope. Fish will scratch against objects and appear listless. A grayish film may form on the body. Rapid breathing in fish may be accompanied by gasping at the surface of the water, or the fish sitting on the bottom of the aquarium. Gills undergo severe damage, leading to suffocation and death. 	<p>GENERAL CURE™</p> <p>For a secondary infection medication, use the following together: MELAFIX and PIMAFIX</p>	<p><i>Dactylogyrus</i> and <i>Gyrodactylus</i> are parasitic worms, commonly called flukes, that attack fins, skin and especially gills of fish. Parasitic worms are frequently found on newly imported fish. The worms attach to the skin of fish via hooks, where they can feed on blood and body fluids. Secondary bacterial or fungal infections may occur following infestation by either of these parasites.</p>
 <p>Hole-In-The-Head Disease (<i>Hexamita</i>)</p>	<ul style="list-style-type: none"> The most obvious symptom is the pitting and erosion of skin and muscle tissue around the face of the fish. This erosion appears to be a symptom of the parasite's presence in the intestinal tract, not on the surface of the fish. Many fish exhibit poor appetite, weight loss and nervousness; without proper treatment, death ultimately results. 	<p>GENERAL CURE</p>	<p><i>Hexamita</i> and/or <i>Spironucleus</i> parasites infect the intestinal tract of many tropical fish, especially cichlids.</p>
 <p>Dropsy and Malawi Bloat</p>	<ul style="list-style-type: none"> Fish develop a bloated appearance due to accumulation of fluid in the body cavity. Scales may appear to stick out from the sides of fish. In advanced cases, fish lose the ability to swim and may float upside down. 	<p>MELAFIX or PIMAFIX</p> <p>For an alternative medication, select one of the following treatments: FURAN-2, TRIPLE SULFA, FIN & BODY CURE, E.M. ERYTHROMYCIN and add AQUARIUM SALT to reduce fluid accumulation.</p>	<p>Internal <i>Aeromonas</i> bacterial infections most commonly cause this disease. Viral and internal parasitic pathogens (<i>Myxobolus cerebralis</i>) have also been indicated, but are untreatable symptoms.</p>
 <p>Bacterial Hemorrhagic Septicemia</p>	<ul style="list-style-type: none"> Fish show blood streaks in the fins and body. 	<p>MELAFIX</p> <p>For an alternative medication, select one of the following treatments: PIMAFIX, FURAN-2, TRIPLE SULFA, E.M. ERYTHROMYCIN or FIN & BODY CURE.</p>	<p><i>Pseudomonas</i>, <i>Aeromonas</i> or <i>Streptococcus</i> bacterial species most commonly cause these symptoms.</p>

DIAGNOSING & TREATING SICK FISH

APPEARANCE	DESCRIPTION	SUGGESTED TREATMENT	CAUSATIVE AGENT
 <p>Eye Cloud, Body Slime</p>	<ul style="list-style-type: none"> Eyes develop a whitish haze and/or protrude from the head. Hazy or slimy patches appear on the bodies of fish. If infested with parasites, fish may scratch on objects in the aquarium and exhibit rapid breathing. 	<p>MELAFIX</p> <p>For an alternative medication, select one of the following treatments: PIMAFIX, FURAN-2, TRIPLE SULFA, E.M. ERYTHROMYCIN™ or FIN & BODY CURE.</p>	<p>Bacterial pathogens include <i>Pseudomonas</i>, <i>Mycobacterium</i> or <i>Streptococcus</i>. Parasitic pathogens include <i>Trichodina</i>, <i>Ichthyobodo</i>, and <i>Chilodonella</i>. See Subclinical Parasitic Infection below, if fish are scratching.</p>
 <p>Ich (Ichthyophthirius)</p>	<ul style="list-style-type: none"> Early symptoms of this infection in fish include darting in the aquarium and scratching against the gravel and ornaments. Fish exhibit labored breathing and may remain at the water's surface, near filters and aeration devices. White spots may or may not be visible on fish. 	<p>SUPER ICK CURE™</p> <p>In addition, add AQUARIUM SALT to replace electrolytes.</p>	<p>Ich, a protozoan parasite, also known as white spot disease, is caused by the external parasite <i>Ichthyophthirius multifiliis</i>. This microscopic parasite has a multi-staged life cycle and is invisible during its theront stage. Theronts burrow into gill and skin tissue, causing severe electrolyte loss and gill damage and prompting secondary bacterial and/or fungal infections.</p>
 <p>Subclinical Parasitic Infestation</p>	<ul style="list-style-type: none"> Fish may scratch on objects in the aquarium. Slimy skin may develop on fish and fins may be clamped. Labored breathing may be observed. 	<p>SUPER ICK CURE</p> <p>In addition, add AQUARIUM SALT to replace electrolytes. For alternative treatment and both MELAFIX and PIMAFIX.</p>	<p><i>Trichodina</i>, <i>Ichthyobodo</i>, and <i>Chilodonella</i> are protozoan parasites that infect the skin and gills of fish. These parasites have a multi-stage life cycle, similar to Ich, and are often microscopic. They burrow into gill and skin tissue, causing severe electrolyte loss and gill damage and prompting secondary bacterial and/or fungal infections.</p>
 <p>Open Red Sores</p>	<ul style="list-style-type: none"> Fish exhibit open red sores on the body. 	<p>MELAFIX</p> <p>For an alternative medication, select one of the following treatments: PIMAFIX, FURAN-2, TRIPLE SULFA, E.M. ERYTHROMYCIN or FIN & BODY CURE.</p>	<p><i>Aeromonas</i> species most commonly cause these symptoms. Red sores may also be caused by high ammonia levels in the water. Test your ammonia level in your aquarium with AMMONIA TEST STRIPS to rule this factor out.</p>
 <p>Mouth Fungus - Saddleback Disease</p>	<ul style="list-style-type: none"> Raised, gray patches are observed on the fins and mouth areas of fish. Live bearers, such as guppies and mollies, develop grayish patches on their backs, giving rise to the name "saddle back disease." Infected areas may develop into red ulcers and infect the gills, causing rapid loss of fish. 	<p>MELAFIX or PIMAFIX</p> <p>For an alternative medication, select one of the following treatments: FURAN-2, TRIPLE SULFA, E.M. ERYTHROMYCIN or FIN & BODY CURE.</p>	<p><i>Flavobacterium columnaris</i> is a common bacterium responsible for this disease.</p>
 <p>Bacterial Gill Disease</p>	<ul style="list-style-type: none"> Fish will scratch against objects and appear listless. A grayish film may form on the body. Rapid breathing in fish may be accompanied by gasping at the surface of the water, or the fish sitting on the bottom of the aquarium. Gills undergo severe damage, leading to suffocation and death. 	<p>MELAFIX</p> <p>For an alternative medication, select one of the following treatments: PIMAFIX, FURAN-2, TRIPLE SULFA, E.M. ERYTHROMYCIN or FIN & BODY CURE.</p>	<p>This bacterial disease can be caused by many pathogens such as <i>Pseudomonas</i> and <i>Mycobacterium</i> species. High ammonia and nitrite levels can also impact gills. Test your ammonia and nitrite levels in your aquarium with a MASTER TEST KIT.</p>